

Dural AVF with Direct Leptomeningeal Venous Drainage

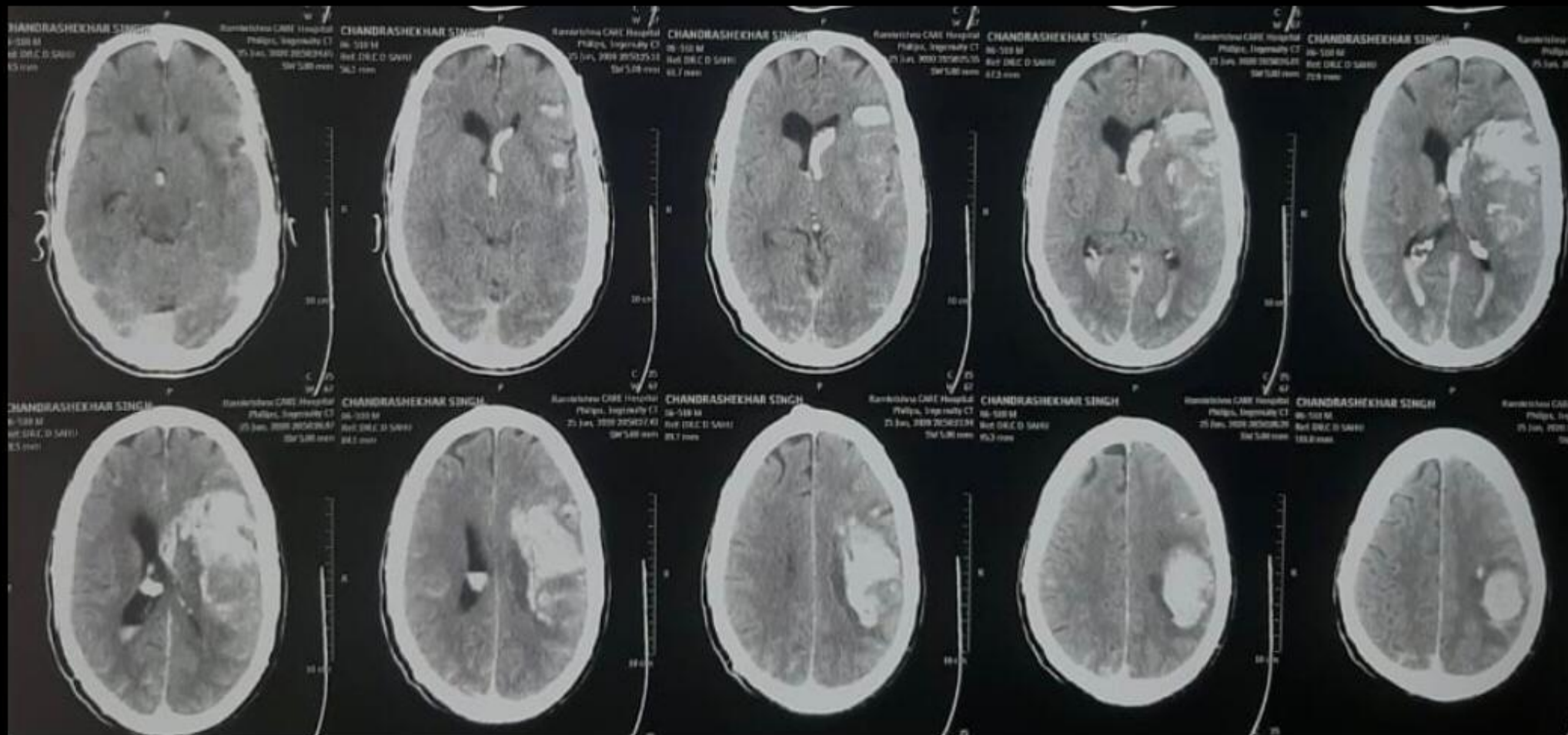
- DAVFs with cortical venous reflux often end up with life threatening neurological events.
- Early diagnosis and treatment are vital in preventing mortality

CASE

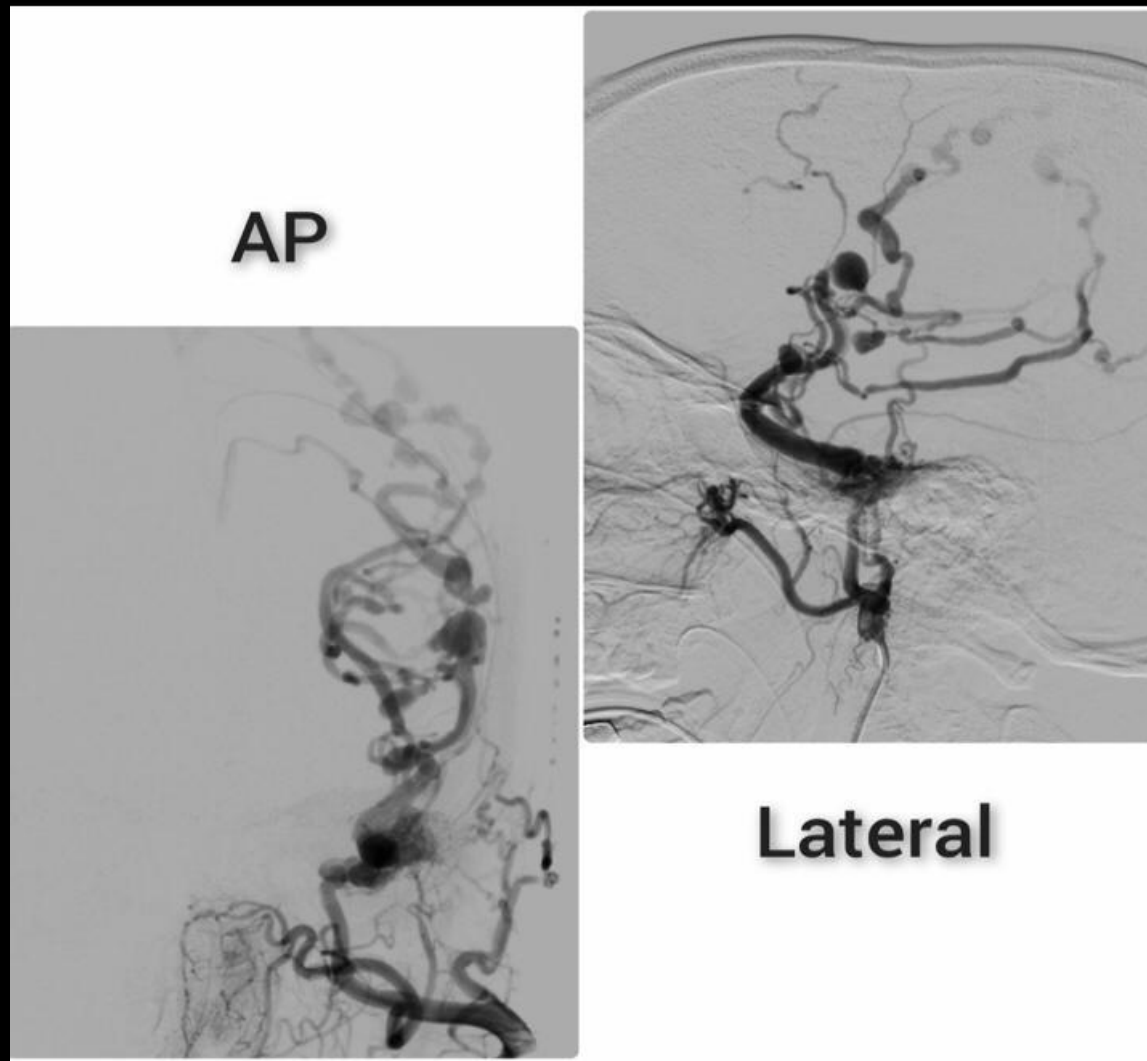
RS M/62 yrs

Sudden severe headache, transient LOC,
hemiplegic

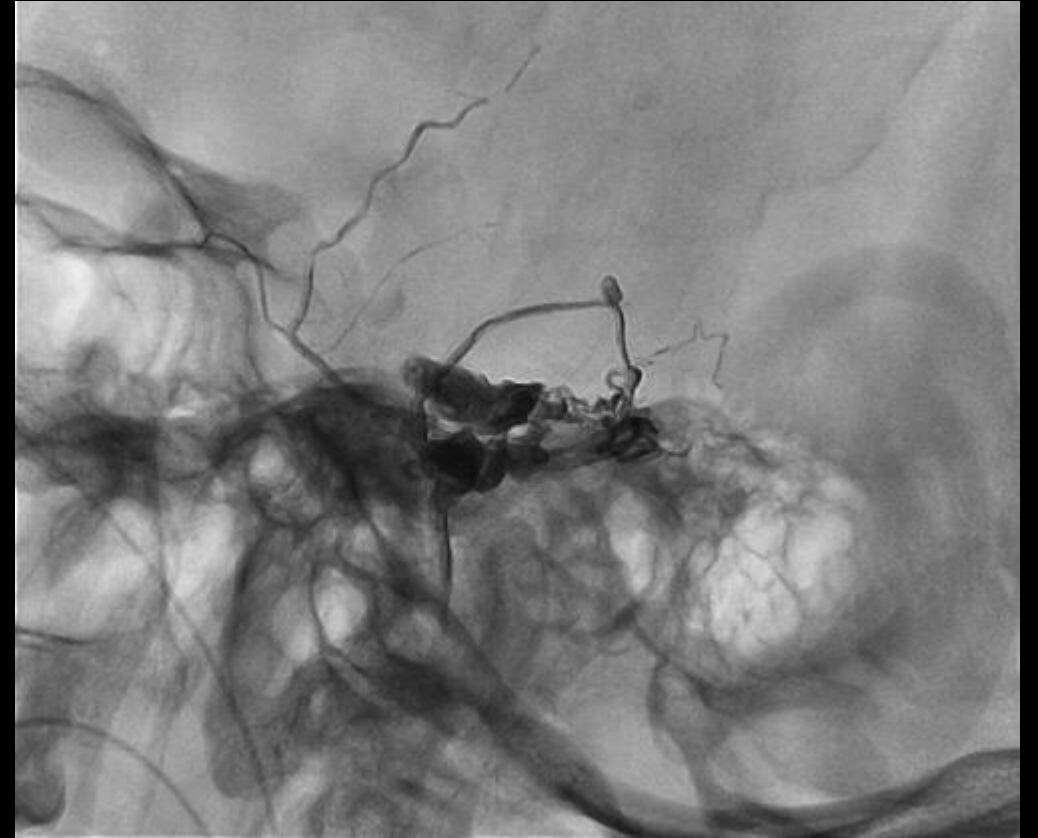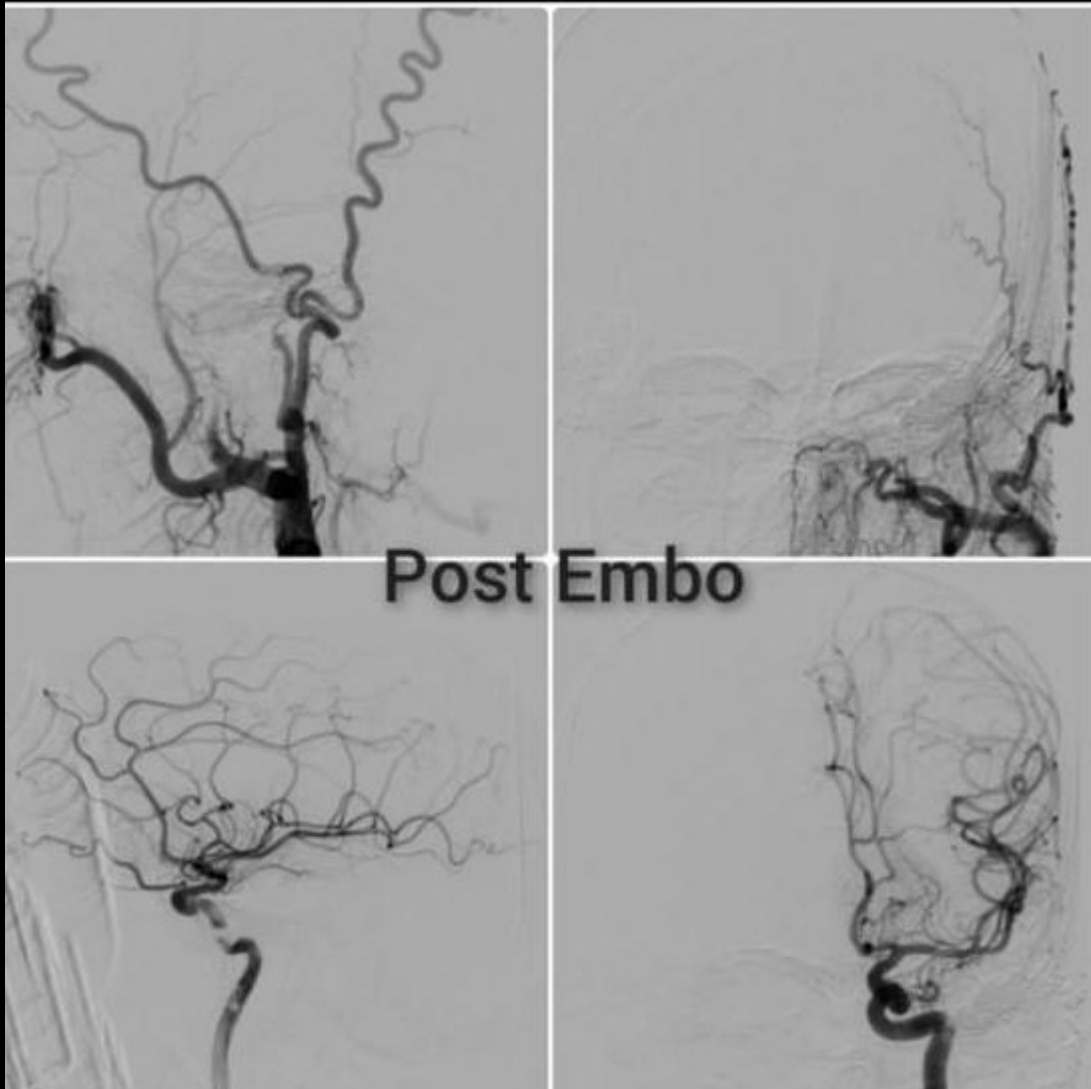
No past H/O trauma or seizures



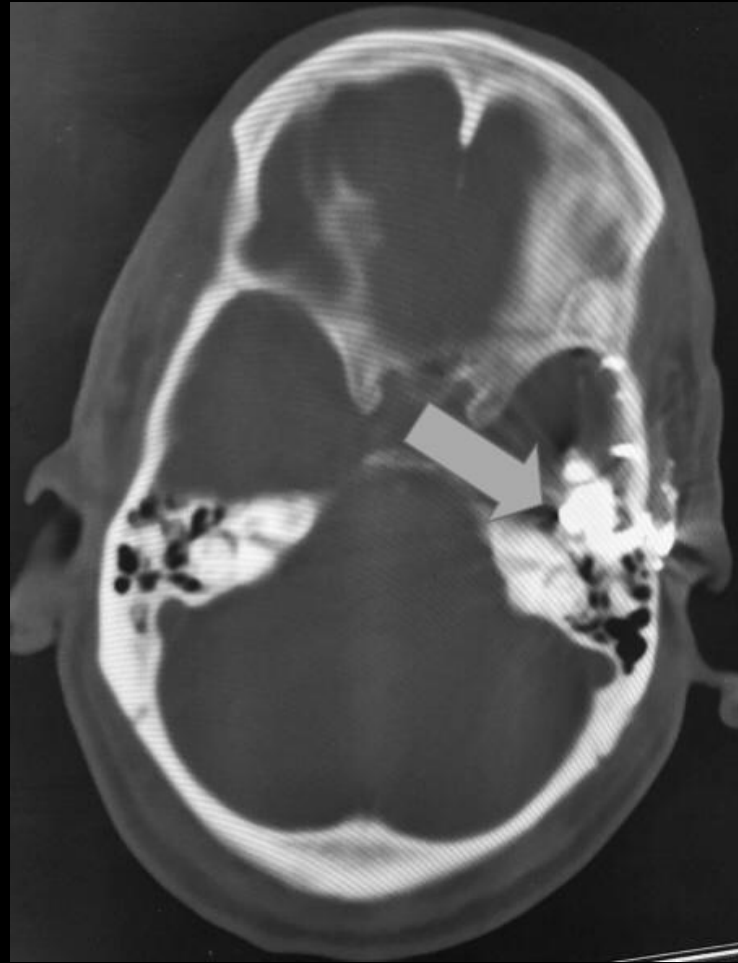Large parenchymal hemorrhage with intra ventricular extension



DSA revealed a DAVF with direct leptomeningeal venous drainage.
Venous dysplasia and multiple aneurysms were seen



Selective embolization led to angiographic cure with elimination of fistula



Skull radiograph and CT show Onyx cast in the fistula.
He was discharged day 10 post treatment MRS of 2 at 3 months follow up.

- Clinical eloquence of a DAVF is primarily dependent upon its venous drainage.
- Closure of the fistula with its vein gives durable cure.
- Endovascular embolization is the preferred treatment modality.

Case Courtesy: C. D. Sahu & Nishant Bhargava,
Raipur