

Out of window MT

Approvals for IV thrombolysis

- Upto 3 hours (1996)
- 4.5 hours (2008)
- Bridging -upto 6 hours (2018)
- MT upto 24 hours now not uncommon

- Each patient tolerates ischemia differently.
- We may depend on DW- T2/ Flair mismatch or CT perfusion to assess the penumbra.

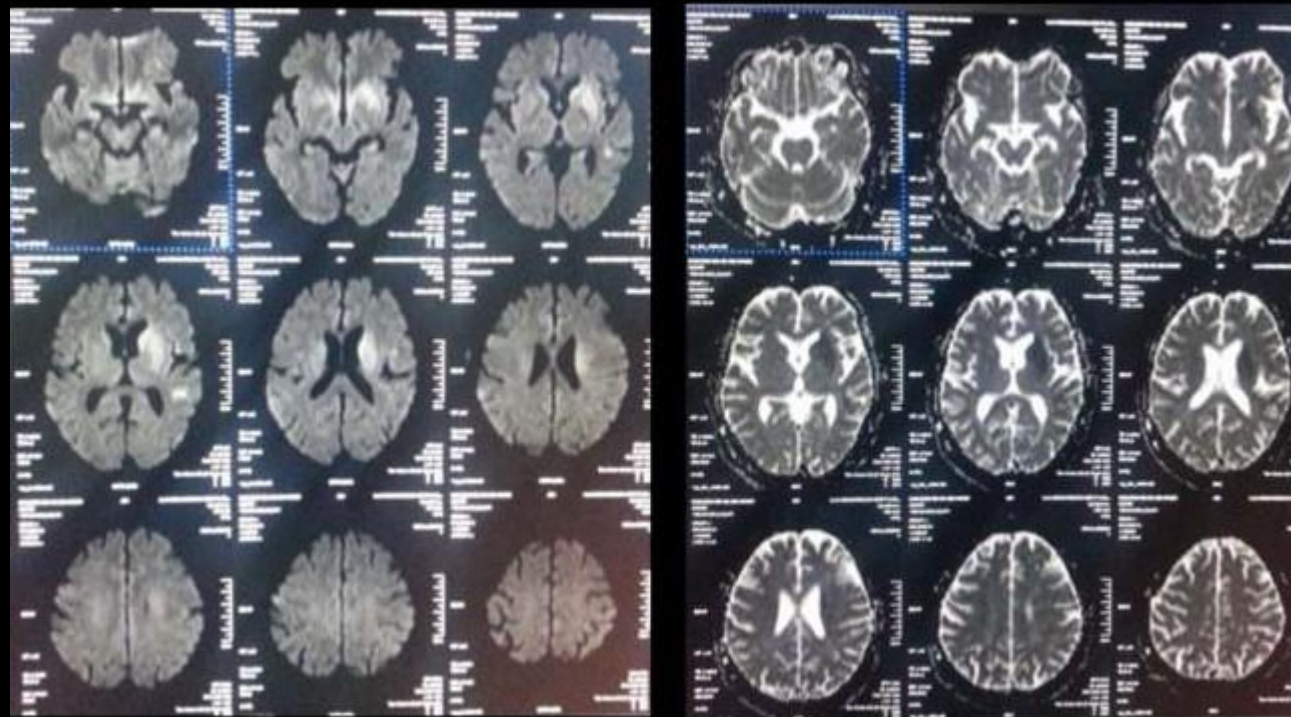
CASE

60/M

Right sided weakness, slurred speech

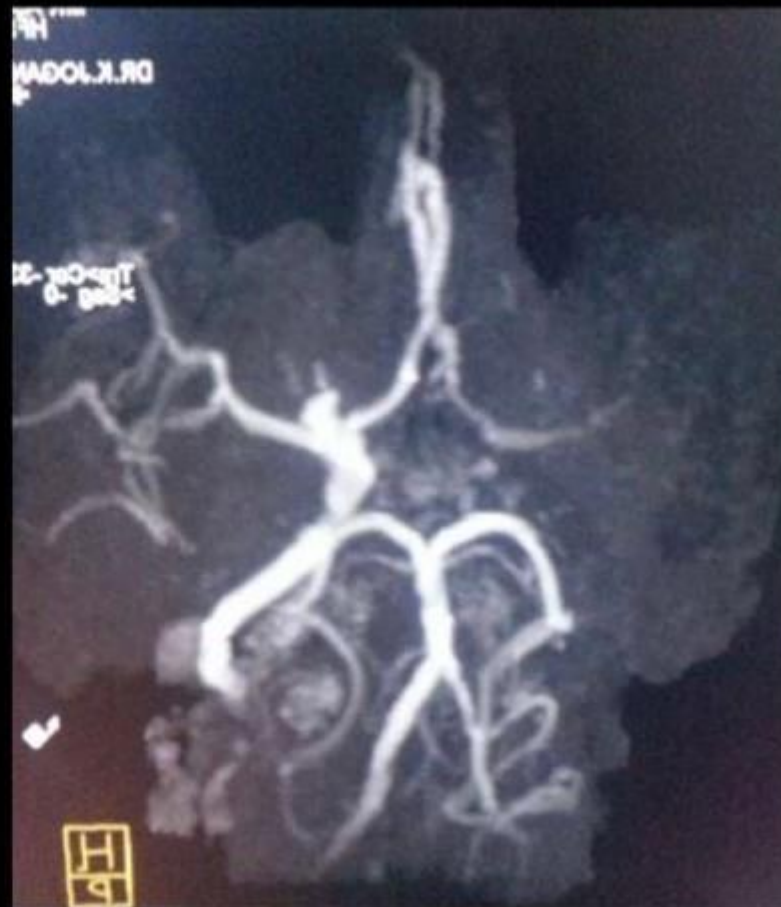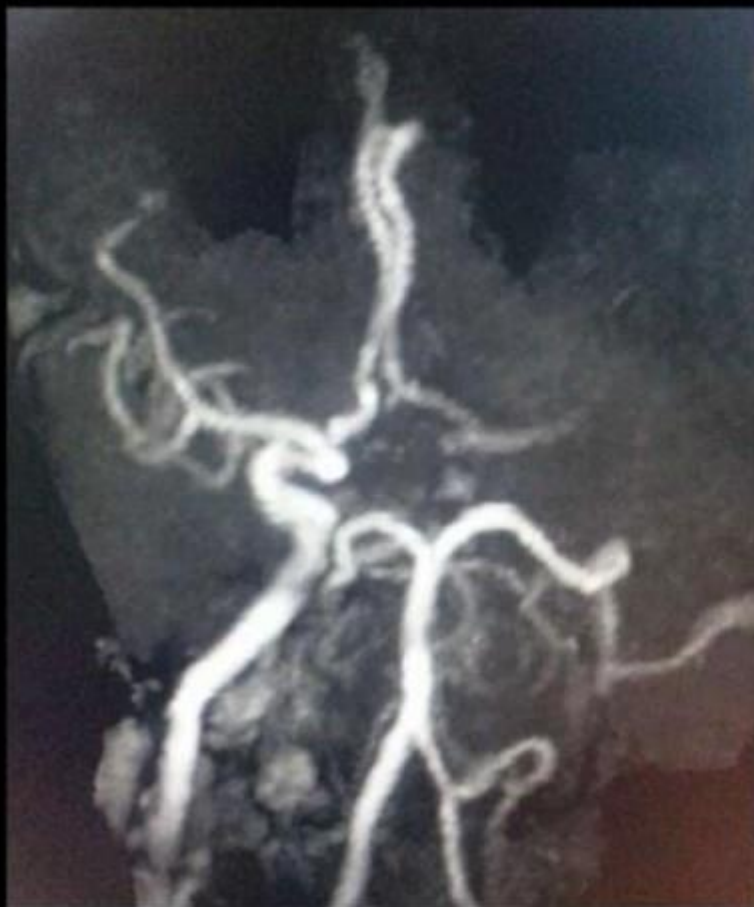Presented 12 hrs after onset

NIHSS 18

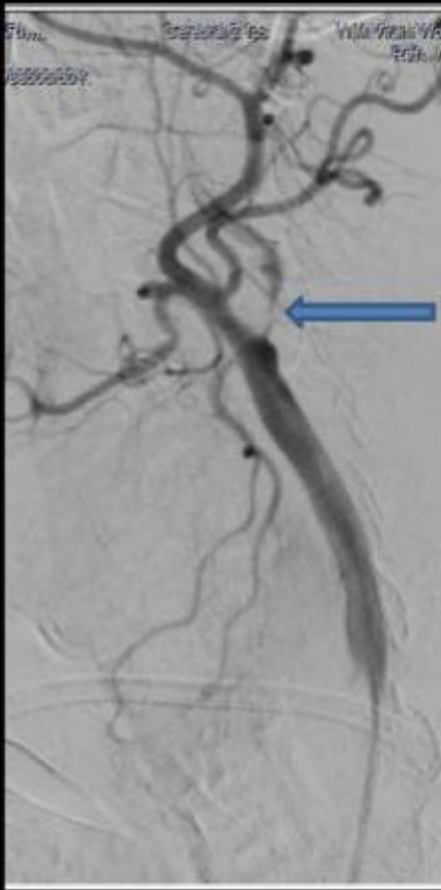

Relatively small DWI defect

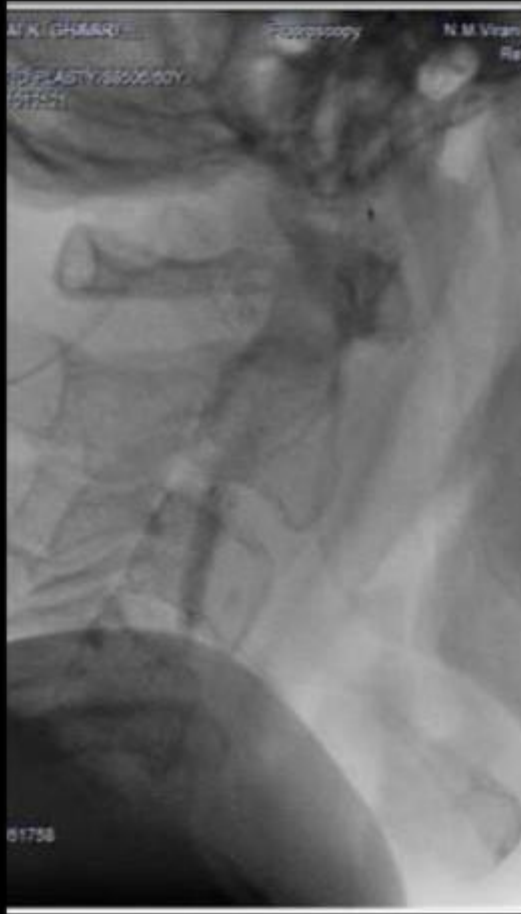MRA



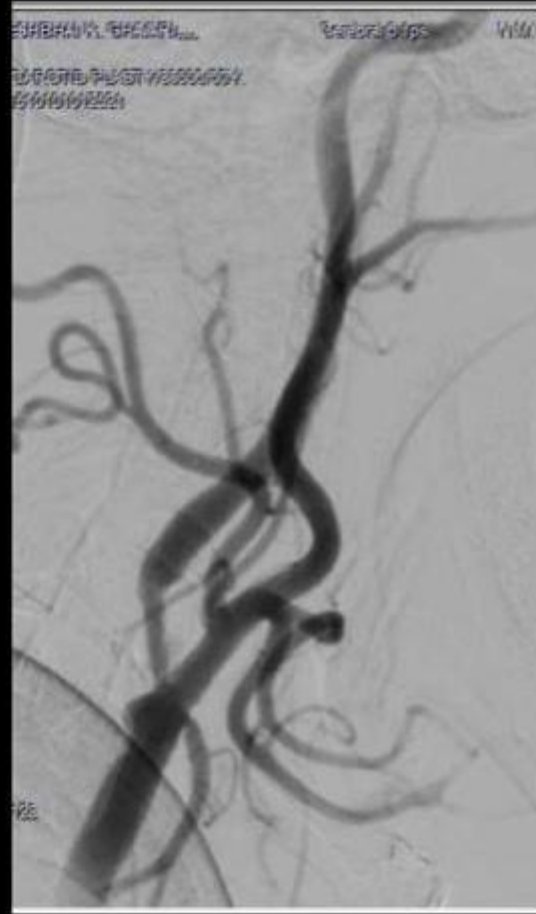Lt ICA + Lt MCA occluded



Stenosis

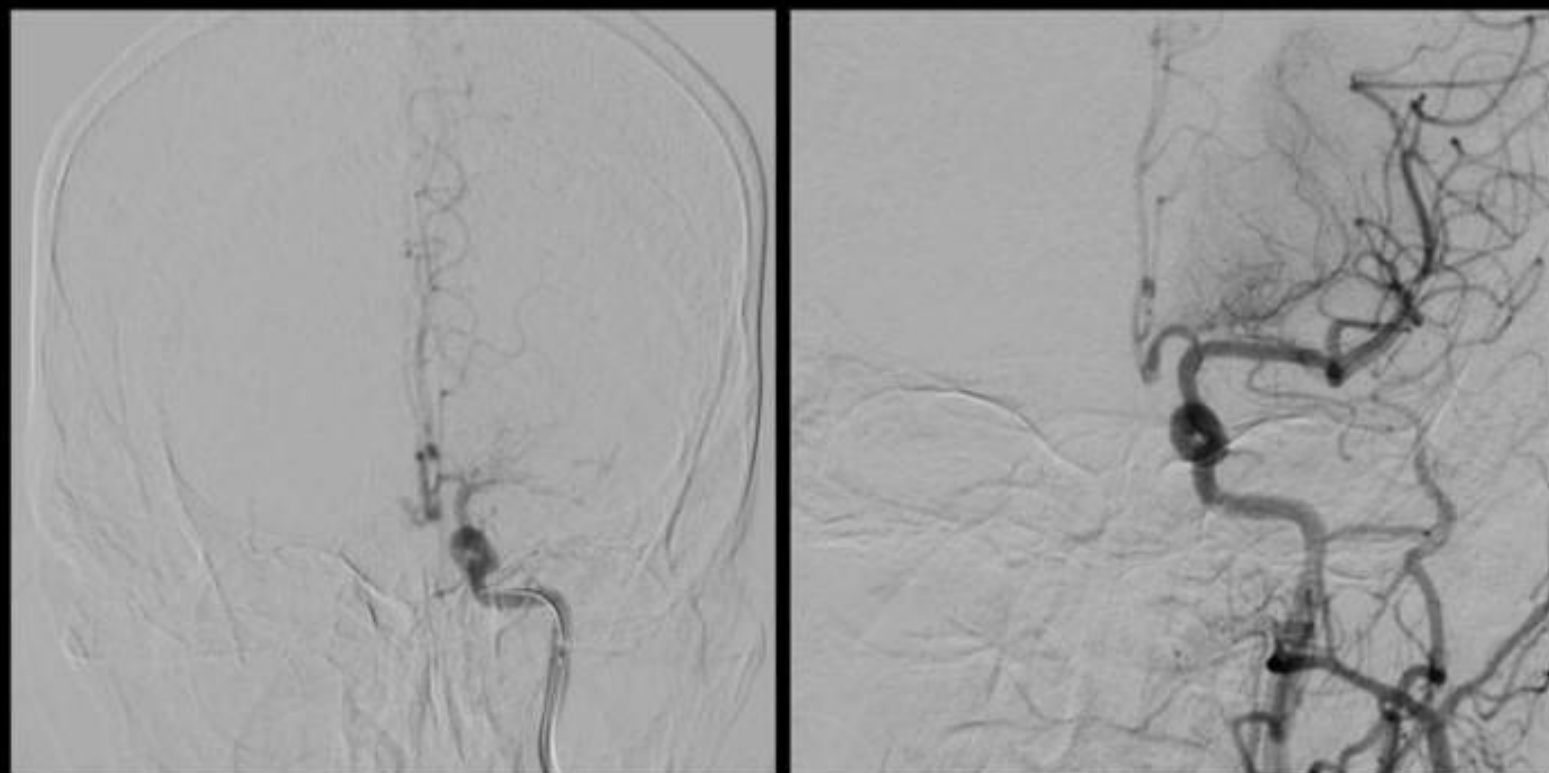


Angioplasty with 4 mm balloon

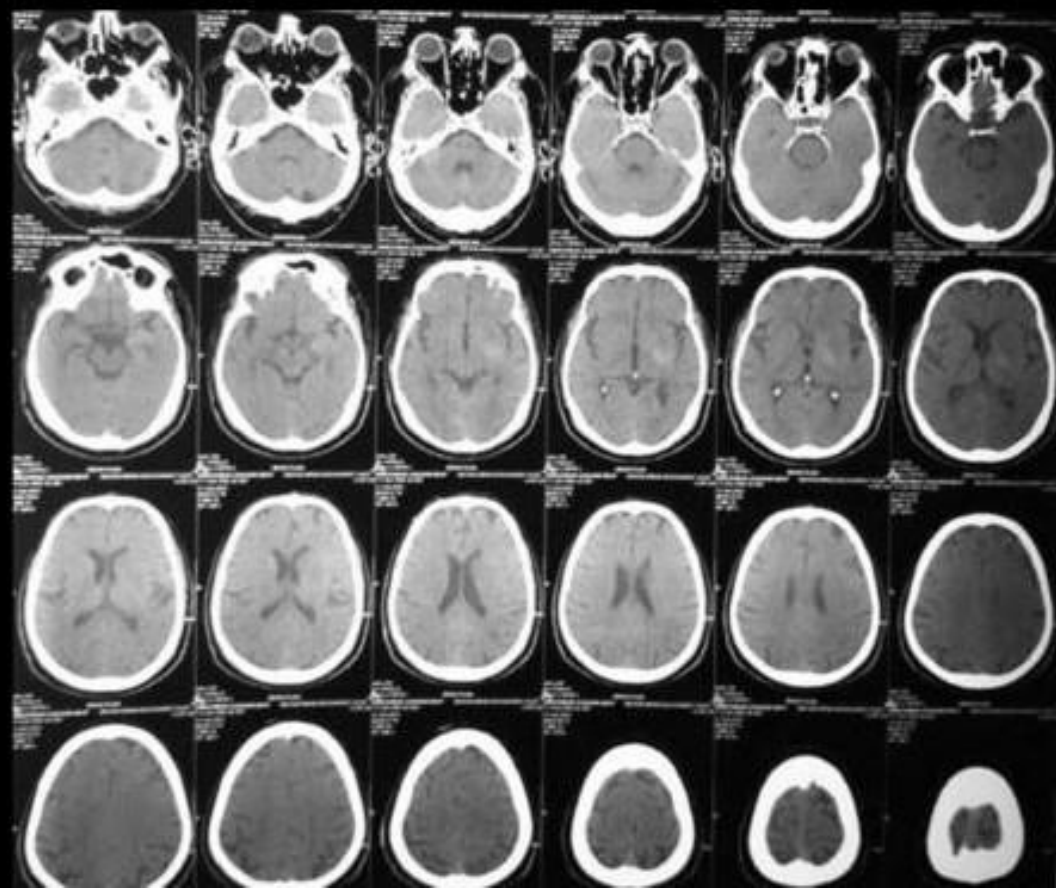


Acute stenting deferred

Stentriever thrombectomy



24 hrs CT



Challenge was formidable.

- 12 hours since symptom onset. High NIHSS.
- Dominant ICA and MCA bifurcation occlusion.
- Decision for MT was purely based on imaging.

- CAS was done after 2 weeks.
- MRS of 1 at 3 months

- There has been a paradigm shift from time window to tissue window.
- Time is brain, but each brain has its own time frame.

Courtesy- Vikash Jain, Rajkot